Beyond the Scope

Open Treatment of Femoroacetabular Impingement

Michael K. Ryan, MD, Thomas Youm, MD, and Jonathan M. Vigdorchik, MD

Abstract

Hip arthroscopy as we know it today developed over the last 15 to 20 years, yet its true beginning is far more dated. Initially developed as a means of removing loose bodies or as a means of lavage, hip arthroscopy was not utilized to treat femoroacetabular impingement (FAI) until much later. Its usefulness as a means of treating FAI did not arise until hip impingement was understood to be causal in the development of degenerative changes of the labrum and articular surfaces. As our understanding of FAI grew, the tools for treating it developed in tandem. Open treatment of FAI had been the first treatment of choice as this allowed for circumferential access to the femoral head, labrum, and acetabulum, which could be done without compromising femoral head perfusion. Yet, as arthroscopic techniques evolved, allowing for better access to the femoral head, labrum, and acetabulum, treatment of FAI with arthroscopy became the norm. However, several recent reports of revision hip arthroscopy for treatment of residual FAI have exposed potential shortcomings of arthroscopic treatment of FAI, specifically limitations with hip arthroscopy's ability to address large or complex cam and pincer deformities. While hip arthroscopy can certainly be useful for treatment of FAI in some patients, we have yet to identify which patients truly benefit from this minimally invasive approach and those who are better served by open surgical techniques. Honing our understanding of the pathology of FAI will help improve patient selection and therefore patient outcomes.

Michael K. Ryan, MD, American Sports Medicine Institute, Birmingham, Alabama, USA. Thomas Youm, MD, and Jonathan M. Vigdorchik, MD, Department of Orthopedic Surgery, NYU Langone Orthopedic Hospital, NYU Langone Health, New York, New York, USA.

Correspondence: Michael K. Ryan, MD, American Sports Medicine Institute, 833 St. Vincents Drive, Birmingham, Alabama 35206, USA; michael.ryan@andrewssm.com.

While hip arthroscopy has only been used to treat femoroacetabular impingement (FAI) for the past two decades, it has existed for over 85 years. Hip arthroscopy was first documented in 1931 by Dr. Michael S. Burman, a Hospital for Joint Diseases faculty member, in an anatomy lab at the New York University Medical School.[1] Dr. Burman was among the few pioneers who realized the promise of arthroscopy for treatment of intraarticular pathology. Dr. Buman, Kenji Takagi, Eugen Bircher, Philip Kreuscher, and Masaki Watanabe innovated techniques to view inside joints without large arthrotomies, leading to hip arthroscopy as we now know it 85 years later.[2] Initially, arthroscopy was used as a diagnostic tool or for simple procedures including lavage, synovectomy, or loose body removal, but technique and instrumentation limitations prevented further treatment using the arthroscope. Burman himself noted the limitations of hip arthroscopy as he encountered difficulty entering the hip joint, noting "distraction was very difficult, more so than any other joint."[1] From 1931 until 1976, hip arthroscopy essential went unexplored until M. Aignan presented his techniques at the International Association of Arthroscopy, which sparked a new interest in hip arthroscopy. R. H. Gross, Lanny L. Johnson, Fayegh Vakili, and Svante Holgersson all described independent techniques and applications of hip arthroscopy within the next five years.[3] J. Serge Parisien added to the development describing his technique for hip arthroscopy with the use of traction on a fracture table and with a 70° arthroscope, though its application was still limited.[3] It was not until the mid to late 1980s that arthroscopic treatment of FAI began. Labrum tears were one of the first pathologic findings to be diagnosed and treated arthroscopically.[4-7] A few years later Reinhold Ganz and his colleagues described the "acetabular rim syndrome," in which dysplastic hips developed labral tears resulting from abnormal forces generated by asymmetric or poorly contained joints.[8] Ganz further described

Ryan MK, Youm T, Vigdorchik JM. Beyond the scope: open treatment of femoroacetabular impingement. Bull Hosp Jt Dis. 2018;76(1):47-54.

how aspherical femoral heads with a shallow head-neck taper and low head-neck offset cause impingement of the labrum and articular surface with flexion and internal rotation, known as the cam-effect.[9] Ganz's novel observations regarding labral tears and the interaction of an imperfectly congruent hip joint, both of which cause hip pain and joint damage, started the discussion and inspired research on what we know today as FAI. Despite the recognition of FAI's role in labral tears and chondral injury, open treatment was still the gold standard in the early 2000s. The open surgical hip dislocation, as described by Ganz, which required a trochanteric osteotomy, meticulous dissection to preserve femoral head blood supply, and an extensive capsulotomy, was the primary method of treating large cam deformities, labral tears, and other intra-articular pathology.[10] Four years later, arthroscopic treatment of FAI began to take off, but in its infancy, it required a combined arthroscopic and open approach to adequately access the femoral head-neck junction.[11] Therefore, hip arthroscopy for treatment of FAI did not evolve into its current form until the mid 2000s, allowing for arthroscopic labral repair, reconstruction, acetabuloplasty, and femoroplasty. As a successful, minimally-invasive alternative to open surgical hip dislocation, hip arthroscopy has become the most frequently used technique for surgical treatment of FAI. However, recent literature regarding failures, revision arthroscopic hip surgery, and a steep learning curve, have called into question whether hip arthroscopy is the best technique for all types of FAI.[11-16]

Femoroacetabular Impingement

Combining Ganz's separate descriptions of the acetabular rim syndrome and cam deformities of the proximal femur, femoroacetabular impingement (FAI) was initially described as a comprehensive entity in the early 2000s, as a purely mechanical process in which subtle anatomic aberrances of the acetabulum or proximal femur lead to abnormal bony and soft tissue contact during motion. Over time, this abnormal contact may cause labral tears, articular damage, and joint degeneration.[9,17,18] Three types of FAI exist—pincer, cam, and combined (Fig. 1)—and each demonstrates unique pathologic characteristics and bears a predilection to a specific demographic. The prevalence of cam, pincer, and combined-type FAI has been extensively studied in a variety of populations, but the overall prevalence of each type is variable. Rates of asymptomatic cam-type deformity range from 14% to 23% in the general population, but are higher in the athletic population, approaching 55%.[19,20] In symptomatic individuals surgically treated for FAI, cam-type deformity has been found to be present in 48% of hips, while combined and isolated pincer-types represented 45% and 8%, respectively.[21] Notably, of those undergoing surgery for treatment of FAI, 93% demonstrated chondrolabral injury at the time of surgery.[21]

From a mechanical perspective, a cam is a device that converts a smooth rotary motion into a reciprocating motion. The cam deformity in FAI is a femoral lesion at the femoral head-neck junction resulting from a loss of sphericity, increased prominence at this junction, and a loss of offset or separation at the head-neck junction.[17] Smooth rotary motion of a completely congruent hip joint is essential for painless and normal motion, and the aberrance of a cam deformity at the head-neck junction leads to increased shear stress on the acetabular cartilage as the prominent cam is forced into the joint. This increased shear stress causes an outside-in delamination of the articular cartilage at the chondrolabral junction extending into the joint at the site of the cam lesion.[18] Over time, the labrum can become detached from the acetabular rim, but this is secondary to

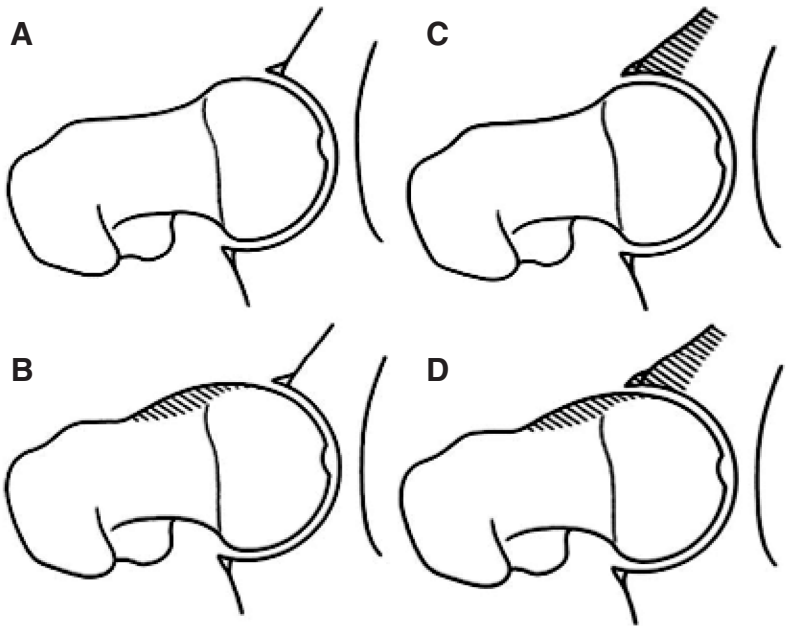

Figure 1 The normal, congruent hip joint (**A**); cam morphology with deformity about the femoral head-neck junction (**B**); pincer morphology with excess bony coverage of the acetabulum (**C**); combined cam and pincer morphology (**D**). (Reprinted from: Grant AD, Sala DA, Schwarzkopf R. Femoro-acetabular impingement: the diagnosis-a review. J Child Orthop. 2012 Mar:6(1)1-12. With permission.)

Table 1 The Most Common Demographic Presentation of Patients with Pincer and Cam Morphology and the Characteristic Types of Associated Pathology (However, Presence of Cam and Pincer Morphology May be Present in a Variety of Patients and Degrees and is Not Limited to One Demographic)

	Pincer	Cam
Age	30-40	20-30
Gender	Female	Male
Pathomechanics	Linear Impact	Shear
Deformity	Overcoverage	Aspherical Femoral Head
Pathoanatomy	1. Labral tear fissuring/degeneration 2. Chondral degeneration 3. Femoral neck herniation cysts 4. Posteroinferior chondral degeneration	1. Chondral avulsion at chondrolabral junction 2. Femoral head herniation cysts 3. Femoral head chondral injury
Characteristic	Ossified labrum Contrecoup lesion	Pistol grip deformity
Location of Failure	Posteroinferior or central	Anterosuperior

the chondral delamination injury.[18] Cam lesions are typically more destructive to the articular surface than pincer lesions. A pincer lesion has been defined as a direct, or linear, contact between the acetabular rim and the femoral neck that compresses the labrum directly causing intrasubstance tears.[17] Chondral injury is typically secondary, limited to a thin rim near the chondrolabral junction and is, therefore, more benign than the damage caused by a cam deformity.[17] Pincer deformity can then be subdivided into global and focal overcoverage depending on the location of the deformity. Global overcoverage includes coxa profunda and protrusio acetabuli, whereas focal overcoverage is either a result of acetabular retroversion (anterior overcoverage) or a prominent posterior wall (posterior overcoverage).[17] Cam and pincer deformities are often present simultaneously, exacerbating the pathologic contact stresses at the hip. Each deformity also demonstrates some unique demographic characteristics (Table 1). The treatment of each, by either open or arthroscopic means, bears a similar goal: to remove or alter the offending pathomechanic deformity and repair the injured labrum to restore the anatomy and forces of a normal hip joint. If accomplished, the overall health of the hip joint may be preserved in this young population, possibly preventing the early development of osteoarthritis, as postulated as early as the 1960s.

Clinical Presentation and Assessment

As awareness and understanding of FAI continues to develop, diagnostic accuracy of hip impingement has improved. However, many patients still experience a significant delay in diagnosis. The majority of patients experience symptoms between 1 and 3 years before receiving a proper diagnosis, with some waiting up to 5 years.[21] Unfortunately, some of these patients undergo unnecessary procedures or surgeries, including lumbar spine surgery, laparoscopy, and hernia surgery.[22,23] This delay and misdiagnosis is multifactorial. Hip pain, while most commonly reported as groin pain, may also be referred to the low back, buttock, thigh, or knee.[22-26] This variable pattern results from several different nerves innervating the hip—the obturator, femoral, and superior gluteal nerves all provide sensory, proprioceptive, and nociceptive fibers to the hip capsule and labrum.[27-29] Without proper examination of the hip, referred pain may be misleading. A detailed patient history should identify either a traumatic or insidious cause of hip pain that is exacerbated by prolonged sitting, squatting, pivoting, or crossing one's legs.[22-24] Mechanical symptoms, such as clicking, popping, or locking, may be present as well, and in some instances subjective feelings of instability may be present.[30] Thorough examination of the hip requires evaluation of range of motion, including hip flexion and extension, as well as internal and external rotation with varying degrees of flexion. Provocative maneuvers include flexion adduction and internal rotation (FADIR) and flexion abduction and external rotation (FABER) tests.[31]

Appropriate imaging is necessary to supplement a thorough patient history and physical examination. Radiographic assessment of the hip and pelvis is more complex and its abnormalities subtle, which can make for a more difficult diagnosis. A satisfactory battery of conventional radiographs of the hip includes a well-positioned anteroposterior (AP) of the pelvis, AP and frog (or cross-table) lateral of the hip, Dunn views, and a false profile view.[32] Each of these distinct views provides important information regarding the morphology of the pelvis, acetabulum, and proximal femur and are often more important in the setting of FAI than magnetic resonance imaging (MRI). However, a contrast MRI will provide additional information about the type and extent of a labral tear as well as the condition of the articular surfaces.[33] Additional imaging, including computed tomography (CT) and three-dimensional (3D) MRI or CT can provide higher-quality detail about the shape and size of cam deformities and are helpful for surgical planning.[34,35] After satisfactory evaluation and imaging,

treatment of FAI includes a variety of non-operative and operative possibilities.

Hip Preservation

While the short-term goal of treating FAI involves fixing the torn labrum and removing any cam or pincer lesions, the long-term goal is hip preservation in order to delay or prevent early degeneration of the hip joint. Abnormal hip anatomy leads to abnormal hip contact and loading, which in turn causes gradual degenerative changes in the hip. This was recognized as early as 1965 by R.O. Murray, who believed that a majority of patients who developed idiopathic or "primary" hip osteoarthritis did so because of subtle anatomic variants that could be detected with more critical evaluation of pelvic radiographs.[36] Murray found that in those who had been diagnosed with osteoarthritis based on symptoms and radiographs, many demonstrated subtle radiographic deformity of the acetabulum (26%) or proximal femur (40%).[36] In a 1976 study of 327 patients, Solomon[37] further proposed that osteoarthritis of the hip was secondary to some anatomic, vascular, or inflammatory pathology and not idiopathic in nature. He suggested that osteoarthritis of the hip is *always* a result of an underlying abnormality of the joint, though it may not be obvious at first glance.[37] His data suggested that 39% of those with osteoarthritis of the hip exhibited radiographic evidence of acetabular dysplasia (20%) or "tilt deformity" (19%), which was later defined as a cam.[37]

As the diagnostic and surgical techniques evolved, closer and more thorough assessment of the labrum and articular surfaces became easier. Building on Murray's and Solomon's hypotheses, McCarthy was one of the first to report on the relationship between a labral tear and chondral injury, demonstrating in an arthroscopic study that 73% of patients with labral fraying or tearing demonstrated articular damage.[38] The importance of an intact labrum in maintaining normal hip loading forces has been demonstrated in several biomechanical analyses. The labrum is key in creating a seal in the hip joint, thereby maintaining hydrostatic fluid pressures and decreasing cartilage consolidation with loading, as well as maintaining normal joint contact areas and pressures.[39-43] The theory that FAI has a notable role in the development of osteoarthritis of the hip has been further studied and supported as imaging and surgical techniques have evolved. Ganz et al.[18,44] reported on over 600 surgical hip dislocations for treatment of FAI and noted that lesions occurring as a result of subtle morphologic deformities seen in FAI act as a precursor to early degenerative disease.[4] Clohisy et al.[45] retrospectively reviewed over 600 patients who had undergone total hip arthroplasty at an average age of 40 years and found 121 patients with an unknown cause of arthritis, all of whom demonstrated a high prevalence of structural abnormalities associated with FAI. Of the 121 with an unclear etiology for osteoarthritis, 76 (63%) demonstrated radiographic findings of cam impingement, 7 (6%) pincer impingement, and 35 (30%) combined cam and pincer impingement.[45] It is therefore apparent that the presence of FAI deformity in the otherwise normal appearing hip is causative in the early degeneration of the hip joint. While long-term data will be needed to definitively prove the long-term benefits and hip-preserving role of surgically correcting FAI, surgical treatment has already been shown to improve pain and function.

Evolution of Surgical Treatment

While conservative treatment of FAI, including anti-inflammatory medications, activity modification, and physical therapy, are recommended as the first step in treatment, little evidence exists to support its use.[46] Patients who do fail these treatment modalities are frequently considered for surgical management. Ganz et al.[10] initially described the open surgical hip dislocation in 2001 as a means of treating labral tears, chondral lesions, and cam and pincer deformities of the hip seen in FAI. With this technique, near-360° visualization and access to the acetabulum and femoral head-neck junction is possible without compromising the blood supply to the femoral head, thereby reducing the risk of avascular necrosis.[18,47] The primary indications for surgical dislocation of the hip at the time included diagnosis and treatment of intra-articular pathology, including labral tears, cartilage lesions, loose bodies, and pincer and cam deformities, and given the primitive state of hip arthroscopy it was believed that this technique was superior in its ability to preserve the hip.[10,18] For over a decade surgical dislocation of the hip was the preferred method for diagnosis and treatment of intra-articular hip pathology, yet improved instrumentation and evolving techniques eventually pushed hip arthroscopy to the forefront of hip preservation. In support of arthroscopic treatment of FAI, two separate studies employed a cadaveric model to demonstrate both efficacy and equivalence of arthroscopy in its ability to resect a similar volume, arc, and depth of bone along the femoral head-neck junction when compared to open treatment.[48,49] Furthermore, and more importantly, the safety of arthroscopic femoroplasty was also demonstrated in a similar comparative cadaveric model in which the main branches of the medial femoral circumflex artery, located at the between the 9:00 and 12:00 position, were unharmed during arthroscopic femoroplasty.[50] The location of the main perforating vessels and the recommended "safe zones" have been confirmed by other reports as well, indicating that arthroscopic treatment of FAI is as safe as open treatment with regard to preserving femoral head blood supply during femoroplasty.[51-53] With the understanding that hip arthroscopy was not only safe but just as effective as surgical dislocation for treatment of FAI, with respect to anatomic and radiographic assessments, proof of clinical benefit was needed to transition much of hip preservation to arthroscopic means. One of the first clinical comparisons of hip arthroscopy and surgical hip dislocation evaluated pre- and postoperative radiographic parameters (head-neck offset and AP α, lateral α, and β angles) and

demonstrated significant improvements in the lateral α angle and head-neck offset within each group but failed to show significant improvement in the AP α and β angles within the arthroscopic group.[54] Importantly, the reduction in the AP α angle was significantly better in the open group compared the arthroscopic group, which has been supported in other studies as well.[54,55] In a systematic review of clinical outcomes comparing open and arthroscopic treatment of FAI, Botser et al.[56] reported the greatest short-term improvement in modified Harris Hip Score, lowest complication rate, and fastest rehabilitation in the arthroscopic group, but indicated much of the results were too heterogeneous to draw definitive conclusions. With the rush of literature arguing in support of hip arthroscopy as the preferred treatment of FAI in the late 2000s and early 2010s, it was difficult to resist a procedure touted to be minimally invasive, as effective and safe at mechanical resection, associated with improved radiographic and clinical outcomes and fewer complications, and linked to a faster recovery.

As a result of the growing popularity of hip arthroscopy for treatment of FAI, the orthopedic world witnessed a significant increase in the number of hip arthroscopies being performed. Over a 10-year period from 1999 to 2009, Colvin et al.[57] reported an 18-fold increase in hip arthroscopy procedures performed by ABOS candidate surgeons. Similarly, Bozic et al.[15] reported over a 600% increase in the incidence of hip arthroscopy procedures performed by ABOS II examinees, but over a period half as long, from 2006 to 2010. Interestingly, many of those who began to perform hip arthroscopy procedures did not undergo fellowship training that focused on hip arthroscopy, and over half performed fewer than 20 hip arthroscopies during their fellowships.[57] In many ways, this trend was beneficial for orthopedics, for sports medicine, and for hip preservation: as awareness of FAI grew, our understanding of hip pathology improved and the techniques with which to treat hip pathology evolved. Yet, as with any new technique, setbacks occurred, and a growing body of literature indicated a need for more thorough assessment and critique of hip arthroscopy in order to better define its ideal applications and inherent limits.[12,14,35,58]

Revision Hip Arthroscopy

Some of the limits of hip arthroscopy became evident in the late 2000s when some of the first revision hip arthroscopy literature was published. One of the innovators and leaders of hip arthroscopy for treatment of FAI, Marc Philippon, was one of the first to publish on revision hip arthroscopy. Philippon reported on 37 hips that underwent revision arthroscopy, 36 (97%) of which had radiographic evidence of persistent FAI at the time of revision surgery.[12] On average, patients underwent revision 20 months after the index surgery, and 34 (92%) reported no resolution of pain after the initial hip arthroscopy.[12] This report established some of the limitations of hip arthroscopy, and subsequent revision articles confirmed the role of incompletely treated or residual FAI in revision hip arthroscopy. In 2012, Clohisy et al.,[13] as a part of the Academic Network of Conservation Hip Outcome Research (ANCHOR) group, reported on a large cohort of revision hip surgeries in which 35% were related to hip arthroscopy for treatment of FAI. They found that persistent structural pathology of the acetabulum or femoral head-neck junction was the most common cause of revision.[13] Specifically, 74% of those with FAI required repeat femoroplasty during the revision procedure, while 65% underwent revision labral fixation or debridement, and 30% needed additional acetubloplasty.[13] Similarly, Bogunovic et al.[14] identified 60 failed hip arthroscopies from over 1,700 surgeries, and of the 37 that underwent a revision hip preservation procedure, 90% of those treated with

Table 2 Summary of Revision Hip Arthroscopy Studies, with Percentages of Those Revised for Femoroacetabular Impingement (FAI) and Hip Dysplasia (DDH)

	Age/BMI/Sex	Time to Revision (mos)	FAI	DDH	Other	% Cam	% Pincer	Chondro-labral injury	Revision Procedure
Bogunovic et al. 2013	28y/25/F(79%)	25	68%	24%	N/A	97%	26%	88%	A – 37% OSHD – 32% PAO – 24%
Clohisy et al. 2012	23y/26/F(71%)	26	30%	30%	SCFE – 23% LCP – 12%	73%	30%	NR	A – 18% O – 72% PAO – 25%
Philippon et al. 2007	33y/X/F(68%)	20.5	97%	8%	Instability – 35%	76%	46%	70%	A – 100%
Larson et al. 2014	29.5y/X/F(56%)	NR	100%	0%	NA	94%	75%	70%	A – 100%
Heyworth et al. 2007	33.6y/X/F(61%)	25.6	79%	0%	Psoas – 29%	33%	58%	79%	A – 100%
Ross et al. 2015	29y/X/F(54%)	NR	90%	0%	AIIS – 10%	86%	54%	NR	A – 100%
Domb et al. 2014	37y/X/F(55%)	22	66%	0%	Instability – 13%	53%	47%	NR	A – 100%

Revision procedures performed were Arthroscopic (A), Open Surgical Hip Dislocation (OSHD), Periacetabular Osteotomy (PAO), or Unspecified Open (O).

revision arthroscopy needed an additional femoroplasty, while 100% treated with open hip dislocation required further femoroplasty. Subsequent reports have implicated persistent structural pathology as the primary reason for failed hip arthroscopy and subsequent revision surgery (Table 2). Larson et al.,[58] who also reported on a series of revisions with persistent cam and pincer deformity (94% and 75%, respectively), further characterized the extent of the persistent deformity and noted mean AP and Dunn α angles of 63° and 66°, respectively, with residual mean head-neck offset of 3.3 mm. Postoperatively, this group found that significant functional improvement correlated with improved head-neck offset, and those with offset of 12 mm to 13 mm demonstrated higher modified Harris Hip Scores (mHHS).[58] Unfortunately, despite this improvement, those undergoing revision hip arthroscopy have demonstrated lower mean functional scores postoperatively compared to those undergoing primary hip arthroscopy for FAI.[12,58-60] Yet, despite the growing understanding that residual deformity is the primary cause of failed hip arthroscopy, and that revision outcomes are inferior to those after primary hip arthroscopy, the majority of hip surgeons continue to utilize arthroscopy only, even as a revision technique.[12,35,58,59,61] Alternatively, Closhisy's and Bogunovic's groups reported on open surgical hip dislocation as a revision technique in 52% and 32% of their revision FAI surgeries, respectively.[13,14] It is unclear at this point if open hip dislocation provides better functional outcomes in the revision setting.

While several factors may contribute to the failure of hip arthroscopy, residual deformity is the primary culprit. Surgeon experience, technical ability, and visualization play roles in optimally treating FAI deformity. The learning curve for hip arthroscopy is much steeper than that for other joints. Unlike the shoulder and knee, the hip joint is deeper, requires traction to access it, is not aligned with a single plane, has more constrained motion, requires an adequate capsular release to navigate arthroscopically, necessitates a 70° scope increasing difficulty of movement and three-dimensional localization and triangulation, and presents complex acetabular and femoral deformity, which can be difficult to visualize. Even highly experienced hip surgeons required a period of 2 years to learn to effectively treat FAI arthroscopically. Buchler's group demonstrated that radiographic parameters did not significantly improve until the third year of performing hip arthroscopy, and even then radiographic osseous correction was less satisfactory in the arthroscopic group compared to the open group.[62] Zaltz et al.[51] also indicated that while hip arthroscopy is a less invasive approach, difficult cases are often highly technically demanding and risk iatrogenic soft tissue and cartilage injury; thus, the potential need for revision surgery is considerable. Boden et al.[16] reported prospectively on 120 cases from a single non-fellowship trained surgeon and found that revision and hip arthroplasty conversion rates for the initial 40 cases were over three times what they where for the final 40 cases. In yet unpublished data, Kester et al.[63] reported on risk factors for revision surgery or conversion to THA after hip arthroscopy in 3,957 patients and found that patients undergoing hip arthroscopy by a surgeon performing less than 40 hip arthroscopies annually were at higher risk for revision or conversion to total hip arthroplasty. These studies indicate that achieving optimal outcomes requires extensive experience, and even with experience, unaddressed residual deformity results in inferior outcomes and higher revision rates.

Arthroscopy Versus Open

What remains to be better delineated is which deformities are adequately treated arthroscopically and which require open surgical hip dislocation. Unfortunately, no standard radiographic, CT, or MRI protocol or classification of deformity has been established to effectively determine this preoperatively. With such a protocol or classification, surgeons may be better able to provide optimal surgery for each individual deformity based on size, location, associated chondrolabral pathology, and proximity to blood supply. While hip arthroscopy is effective at treating most deformity seen with FAI, there may be a tendency for surgeons to underestimate the acetabular or femoral osteoplasty needed during arthroscopy, and inherent technical limitations including access to areas of the hip joint likely exist.[54] Currently, open treatment of FAI is indicated for complex femoral and acetabular deformity, including global acetabular overcoverage, large cam deformities with extension to the posterior and posterolateral aspect of the femoral head-neck junction, focal articular defects, and extra-articular impingement.[13,51,54] Further work is needed to develop more specific and robust recommendations for which pathologies are best treated with open versus arthroscopic surgery.

Conclusion

Hip arthroscopy and hip preservation is a relatively new entity with respect to the history of orthopedic surgery and the treatment of femoroacetabular impingement. From the first hip arthroscopy in the 1930s to the evolution of modern techniques beginning in the mid-2000s, both open and arthroscopic hip preservation techniques continue to progress at a rapid pace. Hip preservation surgeons have demonstrated the efficacy of both open and arthroscopic techniques, yet early arthroscopic revisions warrant concern and further investigation. Proper and complete evaluation and understanding of the patient's pathology and deformity must be made prior to surgery in order to better determine which surgical approach is optimal for each individual patient.

Disclosure Statement

None of the authors have a financial or proprietary interest in the subject matter or materials discussed, including, but

not limited to, employment, consultancies, stock ownership, honoraria, and paid expert testimony.

References

1. Burman MS. Arthroscopy or the direct visualization of joints: an experimental cadaver study. 1931. Clin Orthop Relat Res. 2001(390):5-9.
2. Watanabe M. Memories of the early days of arthroscopy. Arthroscopy. 1986;2(4):209-14.
3. Parisien JS. Arthroscopy of the hip. Present status. Bull Hosp Jt Dis Orthop Inst. 1985;45(2):127-32.
4. Ikeda T, Awaya G, Suzuki S, et al. Torn acetabular labrum in young patients. Arthroscopic diagnosis and management. J Bone Joint Surg Br. 1988;70(1):13-6.
5. Farjo LA, Glick JM, Sampson TG. Hip arthroscopy for acetabular labral tears. Arthroscopy. 1999;15(2):132-7.
6. Fitzgerald RH Jr. Acetabular labrum tears. Diagnosis and treatment. Clin Orthop Relat Res. 1995(311):60-8.
7. McCarthy JC, Lee JA. Arthroscopic intervention in early hip disease. Clin Orthop Relat Res. 2004(429):157-62.
8. Klaue K, Durnin CW, Ganz R. The acetabular rim syndrome. A clinical presentation of dysplasia of the hip. J Bone Joint Surg Br. 1991;73(3):423-9.
9. Ito K, Minka MA 2nd, Leunig M, et al. Femoroacetabular impingement and the cam-effect. A MRI-based quantitative anatomical study of the femoral head-neck offset. J Bone Joint Surg Br. 2001;83(2):171-6.
10. Ganz R, Gill TJ, Gautier E, et al. Surgical dislocation of the adult hip a technique with full access to the femoral head and acetabulum without the risk of avascular necrosis. J Bone Joint Surg Br. 2001;83(8):1119-24.
11. Clohisy JC, McClure JT. Treatment of anterior femoroacetabular impingement with combined hip arthroscopy and limited anterior decompression. Iowa Orthop J. 2005;25:164-71.
12. Philippon MJ, Schenker ML, Briggs KK, et al. Revision hip arthroscopy. Am J Sports Med. 2007;35(11):1918-21.
13. Clohisy JC, Nepple JJ, Larson CM, et al. Persistent structural disease is the most common cause of repeat hip preservation surgery. Clin Orthop Relat Res. 2013;471(12):3788-94.
14. Bogunovic L, Gottlieb M, Pashos G, et al. Why do hip arthroscopy procedures fail? Clin Orthop Relat Res. 2013;471(8):2523-9.
15. Bozic KJ, Chan V, Valone FH 3rd, et al. Trends in hip arthroscopy utilization in the United States. J Arthroplasty. 2013;28(8 Suppl):140-3.
16. Boden RA, Wall AP, Fehily MJ. Results of the learning curve for interventional hip arthroscopy: a prospective study. Acta Orthop Belg. 2014;80(1):39-44.
17. Tannast M, Siebenrock KA. Conventional radiographs to assess femoroacetabular impingement. Instr Course Lect. 2009;58:203-12.
18. Ganz R, Parvizi J, Beck M, et al. Femoroacetabular impingement: a cause for osteoarthritis of the hip. Clin Orthop Relat Res. 2003(417):112-20.
19. Hack K, Di Primio G, Rakhra K, Beaule PE. Prevalence of cam-type femoroacetabular impingement morphology in asymptomatic volunteers. J Bone Joint Surg Am. 2010;92(14):2436-44.
20. Frank JM, Harris JD, Erickson BJ, et al. Prevalence of femoroacetabular impingement imaging findings in asymptomatic volunteers: a systematic review. Arthroscopy. 2015;31(6):1199-204.
21. Clohisy JC, Baca G, Beaule PE, et al. Descriptive epidemiology of femoroacetabular impingement: a North American cohort of patients undergoing surgery. Am J Sports Med. 2013;41(6):1348-56.
22. Clohisy JC, Knaus ER, Hunt DM, et al. Clinical presentation of patients with symptomatic anterior hip impingement. Clin Orthop Relat Res. 2009;467(3):638-44.
23. Burnett RS, Della Rocca GJ, Prather H, et al. Clinical presentation of patients with tears of the acetabular labrum. J Bone Joint Surg Am. 2006;88(7):1448-57.
24. Philippon MJ, Maxwell RB, Johnston TL, et al. Clinical presentation of femoroacetabular impingement. Knee Surg Sports Traumatol Arthrosc. 2007;15(8):1041-7.
25. Lesher JM, Dreyfuss P, Hager N, et al. Hip joint pain referral patterns: a descriptive study. Pain Med. 2008;9(1):22-5.
26. Ryan MK, Beutel BG, Blackmore SA, et al. Mid-term outcomes of hip arthroscopy: does the location of pain lead to predictable outcomes in hip arthroscopy patients. Presented at 2015 International Society for Hip Arthroscopy Annual Meeting, Cambridge, United Kingdom, September 23-26, 2015.
27. Birnbaum K, Prescher A, Hessler S, Heller KD. The sensory innervation of the hip joint—an anatomical study. Surg Radiol Anat. 1997;19(6):371-5.
28. Haversath M, Hanke J, Landgraeber S, et al. The distribution of nociceptive innervation in the painful hip: a histological investigation. Bone Joint J. 2013;95-B(6):770-6.
29. Sakamoto J, Morimoto Y, Ishii S, et al. Investigation and macroscopic anatomical study of referred pain in patients with hip disease. J Phys Ther Sci. 2014;26(2):203-8.
30. Groh MM, Herrera J. A comprehensive review of hip labral tears. Curr Rev Musculoskelet Med. 2009;2(2):105-17.
31. Pacheco-Carrillo A, Medina-Porqueres I. Physical examination tests for the diagnosis of femoroacetabular impingement. A systematic review. Phys Ther Sport. 2016;21:87-93.
32. Clohisy JC, Carlisle JC, Beaule PE, et al. A systematic approach to the plain radiographic evaluation of the young adult hip. J Bone Joint Surg Am. 2008;90 Suppl 4:47-66.
33. Naraghi A, White LM. MRI of labral and chondral lesions of the hip. AJR Am J Roentgenol. 2015;205(3):479-90.
34. Khan O, Witt J. Evaluation of the magnitude and location of Cam deformity using three dimensional CT analysis. Bone Joint J. 2014;96-B(9):1167-71.
35. Ross JR, Larson CM, Adeoye O, et al. Residual deformity is the most common reason for revision hip arthroscopy: a three-dimensional CT study. Clin Orthop Relat Res. 2015;473(4):1388-95.
36. Murray RO. The aetiology of primary osteoarthritis of the hip. Br J Radiol. 1965;38(455):810-24.
37. Solomon L. Patterns of osteoarthritis of the hip. J Bone Joint Surg Br. 1976;58(2):176-83.
38. McCarthy JC, Noble PC, Schuck MR, et al. The Otto E. Aufranc Award: The role of labral lesions to development of early degenerative hip disease. Clin Orthop Relat Res. 2001(393):25-37.
39. Ferguson SJ, Bryant JT, Ganz R, Ito K. An in vitro investigation of the acetabular labral seal in hip joint mechanics. J Biomech. 2003;36(2):171-8.

40. Cadet ER, Chan AK, Vorys GC, et al. Investigation of the preservation of the fluid seal effect in the repaired, partially resected, and reconstructed acetabular labrum in a cadaveric hip model. Am J Sports Med. 2012;40(10):2218-23.
41. Lee S, Wuerz TH, Shewman E, et al. Labral reconstruction with iliotibial band autografts and semitendinosus allografts improves hip joint contact area and contact pressure: an in vitro analysis. Am J Sports Med. 2015;43(1):98-104.
42. Philippon MJ, Nepple JJ, Campbell KJ, et al. The hip fluid seal--Part I: the effect of an acetabular labral tear, repair, resection, and reconstruction on hip fluid pressurization. Knee Surg Sports Traumatol Arthrosc. 2014;22(4):722-9.
43. Nepple JJ, Philippon MJ, Campbell KJ, et al. The hip fluid seal--Part II: The effect of an acetabular labral tear, repair, resection, and reconstruction on hip stability to distraction. Knee Surg Sports Traumatol Arthrosc. 2014;22(4):730-6.
44. Ganz R, Leunig M, Leunig-Ganz K, Harris WH. The etiology of osteoarthritis of the hip: an integrated mechanical concept. Clin Orthop Relat Res. 2008;466(2):264-72.
45. Clohisy JC, Dobson MA, Robison JF, et al. Radiographic structural abnormalities associated with premature, natural hip-joint failure. J Bone Joint Surg Am. 2011;93 Suppl 2:3-9.
46. Wall PD, Fernandez M, Griffin DR, Foster NE. Nonoperative treatment for femoroacetabular impingement: a systematic review of the literature. PM R. 2013;5(5):418-26.
47. Notzli HP, Siebenrock KA, Hempfing A, et al. Perfusion of the femoral head during surgical dislocation of the hip. Monitoring by laser Doppler flowmetry. J Bone Joint Surg Br. 2002;84(2):300-4.
48. Sussmann PS, Ranawat AS, Lipman J, et al. Arthroscopic versus open osteoplasty of the head-neck junction: a cadaveric investigation. Arthroscopy. 2007;23(12):1257-64.
49. Mardones R, Lara J, Donndorff A, et al. Surgical correction of "cam-type" femoroacetabular impingement: a cadaveric comparison of open versus arthroscopic debridement. Arthroscopy. 2009;25(2):175-82.
50. Sussmann PS, Ranawat AS, Shehaan M, et al. Vascular preservation during arthroscopic osteoplasty of the femoral head-neck junction: a cadaveric investigation. Arthroscopy. 2007;23(7):738-43.
51. Zaltz I, Kelly BT, Larson CM, et al. Surgical treatment of femoroacetabular impingement: what are the limits of hip arthroscopy? Arthroscopy. 2014;30(1):99-110.
52. Lavigne M, Kalhor M, Beck M, et al. Distribution of vascular foramina around the femoral head and neck junction: relevance for conservative intracapsular procedures of the hip. Orthop Clin North Am. 2005;36(2):171-6, viii.
53. McCormick F, Kleweno CP, Kim YJ, Martin SD. Vascular safe zones in hip arthroscopy. Am J Sports Med. 2011;39 Suppl:64S-71S.
54. Bedi A, Zaltz I, De La Torre K, Kelly BT. Radiographic comparison of surgical hip dislocation and hip arthroscopy for treatment of cam deformity in femoroacetabular impingement. Am J Sports Med. 2011;39 Suppl:20S-28S.
55. Zhang D, Chen L, Wang G. Hip arthroscopy versus open surgical dislocation for femoroacetabular impingement: A systematic review and meta-analysis. Medicine (Baltimore). 2016;95(41):e5122.
56. Botser IB, Smith TW Jr, Nasser R, Domb BG. Open surgical dislocation versus arthroscopy for femoroacetabular impingement: a comparison of clinical outcomes. Arthroscopy. 2011;27(2):270-8.
57. Colvin AC, Harrast J, Harner C. Trends in hip arthroscopy. J Bone Joint Surg Am. 2012;94(4):e23.
58. Larson CM, Giveans MR, Samuelson KM, et al. Arthroscopic hip revision surgery for residual femoroacetabular impingement (FAI): surgical outcomes compared with a matched cohort after primary arthroscopic FAI correction. Am J Sports Med. 2014;42(8):1785-90.
59. Domb BG, Stake CE, Lindner D, et al. Revision hip preservation surgery with hip arthroscopy: clinical outcomes. Arthroscopy. 2014;30(5):581-7.
60. Aprato A, Jayasekera N, Villar RN. Revision hip arthroscopic surgery: outcome at three years. Knee Surg Sports Traumatol Arthrosc. 2014;22(4):932-7.
61. Heyworth BE, Shindle MK, Voos JE, et al. Radiologic and intraoperative findings in revision hip arthroscopy. Arthroscopy. 2007;23(12):1295-302.
62. Buchler L, Neumann M, Schwab JM, et al. Arthroscopic versus open cam resection in the treatment of femoroacetabular impingement. Arthroscopy. 2013;29(4):653-60.
63. Kester BS, Capogna B, Mahure S, et al. Independent risk factors for revision surgery or conversion to THA after hip arthroscopy: An analysis of 3,957 patients. Presented at 2017 Arthroscopy Association of North America Annual Meeting, Denver, Colorado, May 18-20, 2017.